

ORIGINAL ARTICLE

Primary lymphoma of the trigeminal nerve presenting as infra-orbital paraesthesia: A case report and literature review

Shreya Tocaciu¹  | Michael Dickinson² | Christine Goh³ | Yi Zhao¹ |
Sevastjan Kranz⁴ | David Wiesenfeld¹

¹Department of Surgery, University of Melbourne Royal Melbourne Hospital, Melbourne, Vic, Australia

²Clinical Haematology, Peter MacCallum Cancer and Royal Melbourne Hospital, Melbourne, Vic, Australia

³Department of Radiology, University of Melbourne Royal Melbourne Hospital, Melbourne, Vic, Australia

⁴Anatomical Pathology, Royal Melbourne Hospital, Melbourne, Vic, Australia

Correspondence

Shreya Tocaciu, Oral and Maxillofacial Surgery, Royal Melbourne Hospital, 2N OMFS Office, 300 Grattan St, Parkville, VIC 3050, Melbourne, Australia.
Email: shreyatocaciu@gmail.com

ABSTRACT

Background: Primary lymphoma of the trigeminal nerve is very rare, with only 10 cases reported in the literature. It may present as unexplained paraesthesia of the trigeminal nerve, usually affecting all three divisions of the nerve. To date, a collation of the known cases of primary trigeminal nerve lymphoma is lacking. This study presents a literature review on trigeminal nerve lymphoma, and presents a case to illustrate diagnosis and management.

Methods: The case report of primary trigeminal lymphoma is presented, with long-term follow-up. A review of the known cases of primary trigeminal lymphoma is conducted, demonstrating the current understanding on diagnosis and management of these rare lesions.

Results: A 67-year-old man presented with a 4-month history of infra-orbital paraesthesia. Imaging showed an expanded infra-orbital canal, with changes extending to the vidian canal. The lesion was biopsied via an endoscopic trans-antral approach, and a diffuse large B-cell lymphoma was confirmed. He was managed with multi-agent chemotherapy with a good clinical response.

Conclusions: Although rare, primary trigeminal lymphoma is an important additional differential diagnosis to consider when assessing a new finding of unexplained trigeminal nerve paraesthesia. Central nervous system imaging should be included in the work up of unexplained trigeminal paraesthesia.

KEYWORDS

lymphoma, trigeminal nerve, paraesthesia, cranial nerves, maxillary nerve

INTRODUCTION

Non-Hodgkin lymphoma typically presents with lymphadenopathy, extranodal disease and systemic symptoms. In approximately 5% of patients, the central nervous system is involved as a secondary phenomenon either at presentation or as a site of relapse. By contrast, primary lymphoma of the cranial nerves (CN) is a rare presentation. Primary CN lymphoma tends to occur in older patients, and may be

associated with immunosuppression.¹ Lymphoma of the trigeminal nerve specifically is exceedingly rare with only 10 cases described in the literature.^{2,3} Outside of the brain, lymphoma typically manifests with nodal or extranodal masses which enhance homogeneously on magnetic resonance imaging (MRI), and often shows intense diffusion restriction. Primary trigeminal nerve lymphoma may present as pain or paraesthesia in the distribution of the trigeminal nerve. A primary lymphoma presenting as isolated infra-orbital

nerve paraesthesia has not previously been described. A case of primary trigeminal nerve lymphoma is presented, including diagnostic work-up and management. A literature review of primary trigeminal nerve lymphoma was also conducted on ScienceDirect (Elsevier) and PubMed (National Library of Medicine [MEDLINE]) using the search terms “trigeminal” and “lymphoma”. Cases of metastatic lymphoma were excluded. These findings are summarised and compared to the presented case.

CASE DESCRIPTION AND RESULTS

A 67-year-old man was referred to the Oral and Maxillofacial Surgeon at the Victorian Comprehensive Cancer Centre (VCCC) Head and Neck Unit in Melbourne, Australia, by his general practitioner with a 4-month history of right infra-orbital paraesthesia with numbness extending to the right palate and maxillary teeth. The paraesthesia was associated with occasional sharp shooting pains in the second division of the right trigeminal nerve. He also reported night

sweats to the point of requiring a change of shirt, and jaw pain which was worse with mastication.

He was of Chinese descent, had no other medical problems and was not immunosuppressed. Clinical examination confirmed numbness of the right maxillary nerve territory.

Contrast-enhanced CT demonstrated expansion of the right infraorbital canal, pterygopalatine fossa, foramen rotundum and vidian canal, which on MRI were shown to be occupied by homogeneously enhancing soft tissue that extended posteriorly to enlarge the cavernous sinus (Figure 1). The bone was remodelled, but there was no permeative change or osseous destruction. There was no clinical or regional evidence of distant metastases. The initial differential for this lesion was perineural tumour spread from a cutaneous squamous cell carcinoma or adenoid cystic carcinoma. However, no such primary tumour was present. Nerve thickening due to IgG4-related diseases or nerve sheath tumour was also possible differential diagnoses.

A biopsy of the lesion was undertaken via an endoscopic trans-antral approach (Figure 2). Histopathology demonstrated a large nerve diffusely infiltrated by medium- to

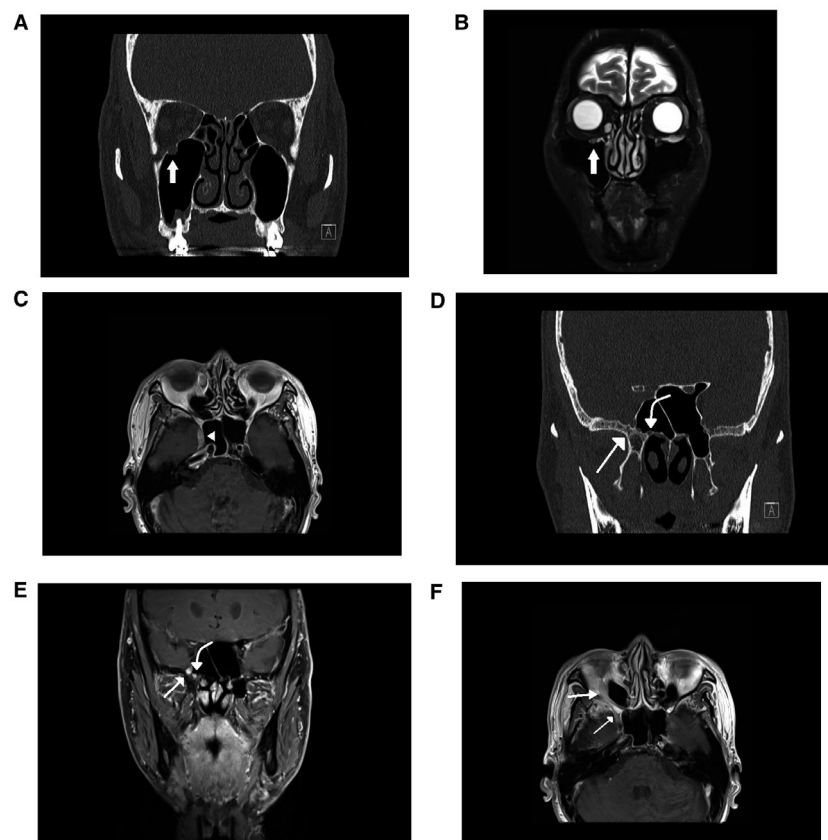


FIGURE 1 (A) Computed tomography (CT) in coronal view demonstrating expansion of the right infraorbital canal (short arrow). (B) Magnetic resonance imaging (MRI) in coronal view demonstrating expansion of the right infraorbital canal (short arrow). An ovoid T2 hyperintense-enhancing mass in the right inferomedial orbit is separate to the trigeminal nerve lesion. (C) MRI in axial view demonstrating extension of the enhancement posteriorly into the cavernous sinus (arrowhead). An ovoid T2 hyperintense-enhancing mass in the right inferomedial orbit is separate from the trigeminal nerve lesion. (D) CT in coronal view demonstrating involvement of the pterygopalatine fossa, expansion of the foramen rotundum (long arrow) and the vidian canal (curved arrow). (E) MRI in coronal view demonstrating involvement of the pterygopalatine fossa, expansion of the foramen rotundum (long arrow) and the vidian canal (curved arrow) by enhancing soft tissue. (F) MRI in axial view expansion of the right infraorbital canal (short arrow) and foramen rotundum (long arrow)

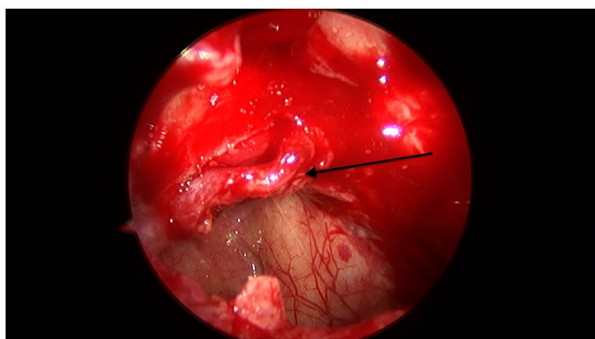


FIGURE 2 Intraoperative photograph showing an endoscopic view of the right maxillary sinus. A 30-degree endoscope was used. A black arrow points to the enlarged intraorbital nerve

large-sized lymphoid cells with markedly pleomorphic nuclei, coarse chromatin and prominent nucleoli (Figure 3). Abundant background apoptotic debris was present. By immunohistochemistry, the atypical lymphoid cells were positive for CD20, BCL-6 and MUM-1, while negative for CD2, CD10, CD30, BCL-2, c-MYC and cyclin-D1. The Ki67 proliferation index was more than 90%. The findings were in keeping with diffuse large B-cell lymphoma, of non-germinal centre type.

A bone-marrow trephine biopsy showed a normo-cellular marrow with no clonal B-cell infiltrate, excluding bony infiltration of the lymphoma. Cytology and flow cytometry of the cerebrospinal fluid were normal. A diagnosis of primary trigeminal diffuse large B-cell lymphoma was made

and the patient was referred to haematological oncologist for management.

A staging positive emission tomogram (PET) showed moderate fluoro-deoxy-glucose avidity in the right Meckel's cave. There was no evidence of regional or distant spread.

The patient was commenced on methotrexate-procarbazine-vincristine-rituximab, a regimen commonly used in CNS lymphoma. Following one cycle, the patient developed palmar-plantar dysesthesia syndrome, a rare but reversible complication of high-dose methotrexate. For this reason, his chemotherapy was changed to standard systemic lymphoma therapy, rituximab-cyclophosphamide-doxorubicin-vincristine-prednisolone (R-CHOP). Methotrexate was delivered between day 11 and 14 of each treatment cycle. The post-treatment course was complicated by grade 1 peripheral neuropathy of the fingertips and toes, but his right infraorbital nerve paraesthesia did not progress. An interim and end-of-chemotherapy complete response was seen on PET imaging. Consolidation radiation was provided to the involved region and the base of skull, sparing the cerebrum. Subtle MRI abnormalities persisted at the end of treatment. Twelve months following chemotherapy, the patient is in remission, with a repeat PET showing no residual avidity, suggestive of a complete metabolic response.

DISCUSSION

Primary cranial nerve lymphoma is exceedingly rare,³ with only nine cases of primary trigeminal lymphoma published

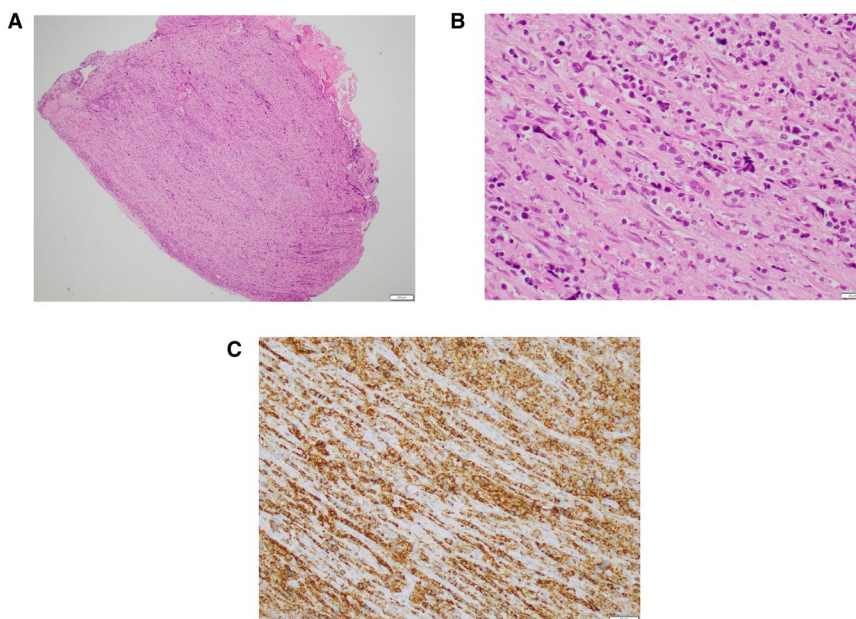


FIGURE 3 Histopathological findings showing diffuse large B-cell lymphoma. (A) Large nerve diffusely infiltrated by lymphoid cells (hematoxylin and eosin stain, x40 magnification). (B) Medium- to large-sized lymphoid cells with marked nuclear pleomorphism, infiltrating between Schwann cells. Abundant background apoptotic debris is also present (haematoxylin and eosin stain, x400 magnification). (C) CD20 immunohistochemical (IHC) stain demonstrating diffuse strong staining of the lymphoid cells (CD20 IHC stain, x200 magnification)

TABLE 1 Reported cases of primary trigeminal lymphoma

Study	Age	Gender	Presentation	Location	Management	Follow-up	Outcome
Present Case	67	M	Paraesthesia V2	Trigeminal trunk	Chemotherapy (R-CHOP) Intrathecal MTX	12 months	No recurrence
Ogiwara et al. ⁴	47	M	Facial pain V1/V2/V3	Trigeminal trunk	Chemotherapy (MPVR) WBRT (45 Gy)	15 months	No recurrence
Iplikcioglu et al. ³	50	M	Paraesthesia V1/V2/V3, diplopia	Trigeminal trunk	High dose MTX, chemotherapy (ARA-C), WBRT (61 Gy)	12 months	No recurrence
Perera et al. ⁵	55	F	Diplopia	Ophthalmic trunk	Not Specified	Not specified	Not specified
Jack et al. ⁶	57	M	Facial pain V1	Meckel's Cave	Chemotherapy (MPVRC)	6 months	No recurrence
Bulsara et al. ⁷	52	F	Paraesthesia V2	Meckel's cave	Not specified	Not specified	Not specified
Kinoshita et al. ⁸	55	F	Paraesthesia V1/V2/V3	Meckel's cave	High-dose MTX, WBRT	Not specified	Not specified
Abdel and Loveren et al. ⁹	40	F	Paraesthesia V1/V2/V3, diplopia	Meckel's cave	Chemotherapy (CAVP), WBRT	Not specified	Not specified
Akaza et al. ¹⁰	60	M	Facial Pain V1/V2/V3	Trigeminal trunk	High-dose MTX, WBRT	30 months	No recurrence
Nakatomi et al. ¹¹	77	M	Paraesthesia V1/V2/V3, diplopia	Trigeminal trunk	Methotrexate, localised radiotherapy (33 Gy), prednisolone	31 months	Death

Abbreviations: R-CHOP, rituximab-cyclophosphamide-doxorubicin-vincristine-prednisolone; MTX, methotrexate; WBRT, whole-brain radiation therapy; ARA-C, cytarabine; MPVR, methotrexate-procarbazine-vincristine-rituximab; MPVRC, methotrexate-procarbazine-vincristine-rituximab-cytarabine; CAVP, cyclophosphamide-adriamycin-vincristine-prednisolone.

Tanaka et al.¹² excluded as case represented lymphoma metastasising to trigeminal nerve, not primary trigeminal nerve lymphoma.

in the literature (Table 1).⁵⁻¹¹ In addition to these cases, one case published by Tanaka et al.¹² describes malignant lymphoma of the caecum metastasising to the trigeminal nerve. Therefore, this case was not included in Table 1.

Of the 10 known cases (nine previously published and the presented case), the average age of diagnosis was 56 years. The male-to-female ratio was 3:2. The majority of cases affected patients of Japanese descent. Patients presented with either facial pain or paraesthesia. Clinical differential diagnoses for this could include perineural invasion from a squamous cell carcinoma (oral cavity or cutaneous) or adenocarcinoma. Primary schwannoma or other tumour of the trigeminal nerve may also present as facial pain or paraesthesia. Other causes of trigeminal nerve dysfunction are outlined in Table 2. In cases of primary lymphoma of the trigeminal nerve, there will be no clinical or radiological signs of infection, trauma or locally advanced tumours. The symptoms will be confined to the distribution of the trigeminal nerve or one of its branches. Although this can also occur in trigeminal neuralgia, there will be an absence of the classic trigger zone and shooting quality to the pain. In cases involving the trigeminal nerve within the cavernous sinus, involvement of the adjacent cranial nerves could also result in diplopia. In patients with diplopia, it was noted that the paraesthesia developed before the diplopia.²

Primary lymphoma of the trigeminal nerve is rare, but has been described in the trigeminal trunk (six of ten cases) or the trigeminal ganglion within Meckel's cave (four of ten cases). The imaging characteristics of homogeneously

TABLE 2 Causes of trigeminal nerve dysfunction.

Pathological process	Examples
Primary malignancy	- Primary trigeminal nerve lymphoma
Infiltration of local malignancy (direct or perineural invasion)	- Oral mucosal squamous cell carcinoma - Cutaneous squamous cell carcinoma - Melanoma - Adenocarcinoma
Infiltration of benign pathology	- Osteomyelitis - Osteoradionecrosis - Medication-related osteonecrosis of the jaws
Trauma	- Mandible fracture - Midfacial fracture - Orbital floor fracture
Infective process	- Odontogenic infection - Fungal infiltrative infection
Facial pain	- Trigeminal neuralgia - Atypical facial pain

enhancing thickening along the maxillary division of the trigeminal nerve and vidian nerve are consistent with the diagnosis of lymphoma. In the presented case, lymphoma was not initially considered as a differential diagnosis due to its rarity. In retrospect, the presence of diffusion restriction within the involved pterygopalatine fossa is a finding that may have raised the possibility of lymphoma.

The approach for biopsy in this case was trans-antral endoscopic via the maxillary sinus. This is in contrast to previously reported cases, which required an open method via lateral suboccipital or infratemporal approaches.³

On biopsy, most primary trigeminal lymphomas were confirmed as diffuse large B-cell lymphomas. As in this case, DLBCL present histologically as collections of medium- to large-sized lymphoid cells with pleomorphic nuclei and prominent nucleoli. These atypical lymphoid cells can be seen to infiltrate the trigeminal neural tissue, and stain positively for CD20, BCL-6 and MUM-1.

A dilemma for the treating haematologist is whether to treat cranial nerve lymphomas like systemic lymphoma, which is conventionally treated with R-CHOP. A concern of this regimen is its limited CNS penetration, and the risk of further dissemination of lymphoma in the CNS. CNS-directed chemotherapy regimens include high-dose methotrexate, but are not targeted to lymphoma. In this case, the treating haematologist used a hybrid regimen incorporating elements of both approaches, in an effort to deliver standard treatment for systemic lymphoma while preventing CNS dissemination.

Of the nine previously published cases of primary trigeminal lymphoma, management was based on a combination of chemotherapy and whole-brain radiotherapy. There was large variation in chemotherapy and radiotherapy regimes described, although most resulted in a good clinical response for a follow up ranging from 6 to 30 months. Of the 10 reported cases, there was one case¹¹ of no clinical response and progression of disease resulting in death.

It can be seen that primary lymphoma of the trigeminal nerve is exceedingly rare and represents a diagnostic and management challenge. Chemotherapy that addresses both systemic and central nervous system compartments must be delivered and radiotherapy may be additive. The prognosis of primary trigeminal lymphoma appears to be better than that of primary CNS lymphoma, where a moderate-risk patient (MSKCC class 2) averages an overall survival of only 3.2 years.¹³ In contrast, with eight of the nine previously published cases with trigeminal nerve lymphoma resulted in a good response to treatment.

CONCLUSIONS

Potential causes of new infraorbital nerve paraesthesia include infection (e.g. sinusitis, odontogenic), trauma and malignancy. As an isolated clinical finding, neoplastic causes such as extension of skull base or maxillary sinus mass, or perineural tumour spread from cutaneous malignancy are the most important diagnostic considerations. Although rare, primary trigeminal lymphoma is an important additional differential diagnosis to consider when assessing a new finding of trigeminal nerve paraesthesia that cannot be explained by clinical examination. Fine slice magnetic resonance imaging should be included in the work up of unexplained trigeminal paraesthesia as it may highlight the characteristic features of a primary

trigeminal lymphoma. A diagnostic biopsy can be obtained by an endoscopic trans-antral approach, and does not require an open approach as previously described.

ACKNOWLEDGMENTS

Ethics approval: not applicable.

CONFLICT OF INTEREST

No conflict of interest to disclose.

ORCID

Shreya Tocaciu  <https://orcid.org/0000-0002-9537-9302>

REFERENCES

- Schabet M. Epidemiology of primary CNS lymphoma. *J Neuro-Oncol.* 1999;43:199–201.
- Thiel E, Korfel A, Martus P, Kanz L, Griesinger F, Rauch M, et al. High-dose methotrexate with or without whole brain radiotherapy for primary CNS lymphoma (G-PCNSL-SG-1): A phase 3, randomised, non-inferiority trial. *Lancet Oncology.* 2010;11(11):1036–47.
- Iplikcioglu AC, Dinc C, Bikmaz K, Ozcan D. Primary lymphoma of the trigeminal nerve. *Br J Neurosurg.* 2006;20(2):103–5.
- Ogiwara T, Horiuchi T, Sekiguchi N, Kakizawa Y, Hongo K. Primary malignant lymphoma of the trigeminal nerve: case report and literature review. *World Neurosurg.* 2015;84(2):592.e3–592.e7.
- Perera C, Fitt G, Kalnins R, Lee S, Gonzalvo A. Lymphoma of the trigeminal nerve – the need for histological diagnosis. *Br J Neurosurg.* 2014;28(2):278–80.
- Jack AS, McDougall CM, Findlay JM. Primary lymphoma isolated to the trigeminal nerve. *Can J Neurol Sci.* 2014;41:103–5.
- Bulsara KR, Kadri PA, Husain M, Al-Mefty O. Malignant lymphoma of the trigeminal region. Case illustration. *J Neurooncol.* 2005;73(3):279–80.
- Kinoshita M, Izumoto S, Oshino S, Nonaka M, Moriuchi S, Maruno M, et al. Primary malignant lymphoma of the trigeminal region treated with rapid infusion of high-dose MTX and radiation: case report and review of the literature. *Surg Neurol.* 2003;60(4):343–8.
- Abdel Aziz KM, van Loveren HR. Primary lymphoma of Meckel's cave mimicking trigeminal schwannoma: case report. *Neurosurgery.* 1999;44(4):859–62.
- Akaza M, Tsunemi T, Sanjo N, Wakimoto H, Kobayashi D, Mizusawa H. Malignant lymphoma presented as left trigeminal neuralgia. *Rinsho shinkeigaku.* Clinical neurology. 2009;49(7):432–6.
- Nakatomi H, Sasaki T, Kawamoto S, Fujimaki T, Furuya K, Kirino T. Primary cavernous sinus malignant lymphoma treated by gamma knife radiosurgery: case report and review of the literature. *Surg Neurol.* 1996;46(3):272–8.
- Tanaka T, Kato N, Itoh K, Hasegawa Y. Long-term survival of Diffuse Large B Cell Lymphoma of the Trigeminal Region extending to the Meckel's cave treated by CHASER therapy: Case report. *Neurol Med Chir.* 2014;54(8):677–80.
- Dolecek TA, Propp JM, Stroup NE, Kruchko C. CBTRUS statistical report: primary brain and central nervous system tumors diagnosed in the United States in 2005–2009. *Neuro Oncol.* 2012;14(S5):1–49.

How to cite this article: Tocaciu S, Dickinson M, Goh C, Zhao Y, Kranz S, Wiesenfeld D. Primary lymphoma of the trigeminal nerve presenting as infra-orbital paraesthesia: A case report and literature review. *Oral Surg.* 2020;00:1–5. <https://doi.org/10.1111/ors.12584>